Coracoid process fracture combined with acromioclavicular joint dislocation and coracoclavicular ligament disruption

K.S. Yu (1), P.T. Chan (1), W.K.Ngai (1), Y.S. Faan (2), W.T. Lo (3)

(1) Department of Orthopaedics and Traumatology, North District Hospital

(2) Department of Physiotherapy, North District Hospital

(3) Department of Occupational Therapy, North District Hospital

Correspondence:

Department of Orthopaedics and Traumatology, North District Hospital, No. 9 Po Kin Road, Sheung Shui, N.T., Hong Kong SAR, China Tel: +852-2683-7588 Fax:+852-2683-7576

E-mail: yuks@ha.org.hk

Abstract

This extremely rare triple injury was treated operatively with screw fixation of the coracoid process, transacromial fixation of the acromioclavicular joint, and repair of the coracoclavicular ligament. The treatment yielded excellent results with good power and full range of motion.

Résumé

Cette blessure triple extrêmement rare a été traitée chirurgicalement avec fixation par vis de la coracoide, fixation trans-acromiale de l#acromio-claviculaire, et réparation du ligament coraco-claviculaire. Le traitement a donné un excellent résultat avec une bonne force musculaire et une mobilité complète.

Introduction

Cases having fracture of the coracoid process combined with an acromioclavicular joint dislocation and coracoclavicular ligaments disruption is rare, with only two adult cases and a pediatric case reported in the English-language literature (Table 1) [6,7,8]. It is important to recognize all three lesions and treat accordingly.

Case-Report

A 37-year-old truck driver sustained a road traffic accident with a left shoulder injury. The truck toppled over onto the left side and the patient fell with his arm adducted, striking the shoulder against a firm object. Physical examination revealed a prominent left distal clavicle and tenderness over the acromioclavicular joint and the coracoid process. The range of motion of the shoulder joint was restricted due to pain. The neurological examination of the upper limb was normal. There was no other major injury. Radiological examination of the shoulder revealed a third degree acromioclavicular joint dislocation and widening of the coracoclavicular distance (Figure 1). Stryker view and CT scan showed a fracture through base of the coracoid process (Figure 2). (Figure 3). He was treated operatively, namely open reduction and internal fixation of the acromioclavicular joint with two 2.0mm smooth Kirschner wires. The coracoclavicular ligaments were found to be avulsed from the coracoid process and was fixed back with a suture anchor (Mitek, Johnson and Johnson) (Figure 4). The coracoid process was fixed with a 6.7 mm diameter-cannulated screw (Alphatec cannulated cancellous screw system, Alphatec). Position of the coracoid process and the screw was confirmed with intraoperative radiographic screening. The patient had an uneventful postoperative course and was discharged on the sixth day after operation with his arm in a sling. Active shoulder motion exercise was started. Two months after operation, the Kirschner wires became loosened and were removed subsequently. Physical examination of the shoulder at six months showed full range of motion. Radiological assessment confirmed union of the coracoid process (Figure 5). (Figure 6). Functional outcome was assessed on the basis of Constant and Murley scoring system at final follow-up 36 months post injury, which was 95. He resumed normal manual duty and showed normal shoulder function without pain.

Discussion

Injury to the acromioclavicular joint is common. The majority of injuries occur when the patient falls with the arm adducted, striking the shoulder against the ground or some other firm object [4,5]. The resultant force produces inferior displacement of the scapula in relation to the clavicle. The acromioclavicular joint injuries consist of a continuum of ligament injuries, beginning with injury to the acromioclavicular ligaments only. With increasing force, the coracoclavicular ligaments become involved, followed by the deltoid and trapezius musculature, and ultimately the overlying fascia is torn [5]. In adults, the coracoid process and the clavicle are stronger than the coracoclavicular ligaments and usually are not damaged [3]. Therefore, in adults almost all the complete acromioclavicular joint dislocation involve a tear of the coracoclavicular ligaments instead of a fracture of the coracoid process. In the case presented, the coracoclavicular ligaments were avulsed from the coracoid process. Therefore, it is unlikely that an avulsion force from the ruptured ligaments causes the coracoid process fracture. Direct trauma to the coracoid process is

unlikely because it is well protected by the clavicle from above. On the other hand the coracoid process fracture may have been caused by a violent pull at the apex of the coracoid process by the conjoined tendon of the short head of the biceps, the coracobrachialis muscles and pectoralis minor muscles [6,7]. Forceful resisted flexion of the arm and elbow in trying to prevent him from falling probably avulsed the coracoid process and caused the fracture. Hence, it is the combination of two forces that appear to be responsible for this extremely rare triple injury; with the direct contusion injury to the shoulder girdle, causing dislocation of the acromioclavicular joint and rupture or avulsion injury of the coracoclavicular ligaments; and a sudden pull on the coracoid process by the conjoined tendons, causing fracture of the coracoid process. All the cases reported were treated operatively. The result was good in general [6,7,8]. Acromioclavicular fixation should be used to stabilize the acromioclavicular joint. Like Jacobs and Lizaur, we believe that early acromioclavicular degeneration is not caused by articular perforation with wires [1,2]. Therefore, transacromial fixation with two smooth wires was chosen as the primary fixation device. The coracoid process was fixed with a cannulated screw under intraoperative X-ray control. This can facilitate correct placement of the screw. Like Rockwood, we believe direct repair or reattachment of the coracoclavicular ligaments back to the coracoid process is important [5]. The coracoclavicular ligaments were explored and were found to be avulsed from the coracoid process; they were fixed back with a suture anchor (Mitek, Johnson and Johnson). Different from the three cases reported, coracoclavicular loop was not used; this can avoid late complication of erosion through the clavicle. Internal fixation allows immediate postoperative rehabilitation with mobilization exercise.

Legends

Table 1: Case Summaries

Zettas and Muchnic (1976)	13	M	Sport injury (playing football)	O: screw fixation of the CP, Mersilene wrap and suture of the coracoclavicular ligaments	Asymtomatic with full ROM at 4 months
Wilson and Colwill (1989)	20	M	Football injury (with coracoclavicular ligament rupture also)	O: ORIF of ACJ with 4.5mm screw for 6 weeks; ORIF of CP with 4.0mm screw ; Dacron prosthesis in a coracoclavicular loop.	Full painless ROM
Wang et al. (1994)	28	M	Motorcycle accident (with coracoclavicular ligament rupture also)	O: ORIF of ACJ with two Kirschner wires for 3 months; ORIF of CP with 4.0mm screw; Marlex prosthesis in a coracoclavicular loop.	Normal function without pain
Yu et al. (2002)	37	M	Road traffic accident	O: ORIF of ACJ with two Kirschner wires for 2 months; ORIF of CP with 6.7mm screw; Mitek suture anchor repair of the coracoclavicular ligament.	Normal function without pain

C: conservative treatment

O: operative treatment

ROM: range of motion

CP: coracoid process

ACJ: acromioclavicular joint

Figure 1: Anteroposterior radiograph of the involved shoulder at the time of injury

Figure 2: Stryker view showed fracture of base of the coracoid process

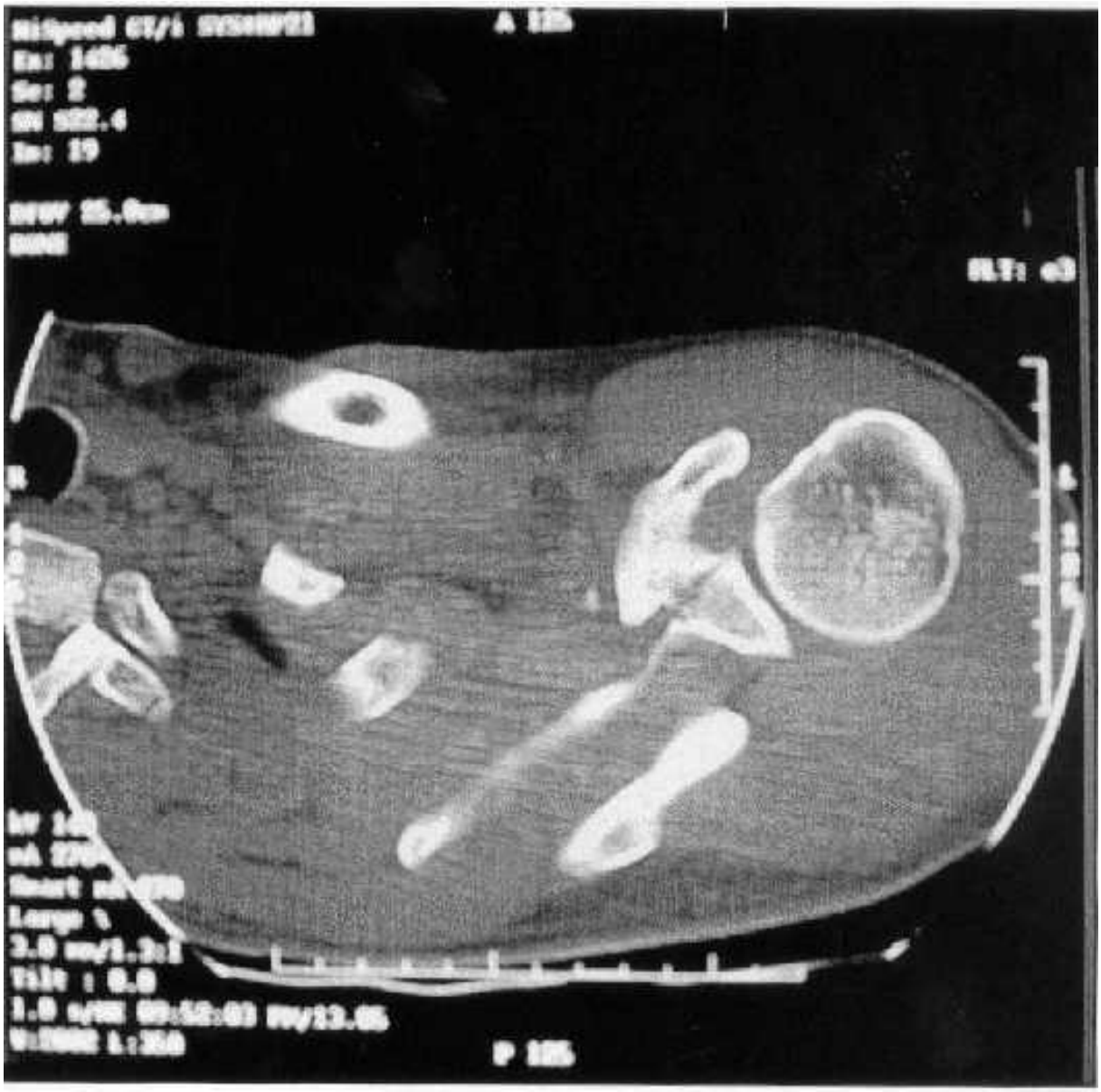

Figure 3: CT scan showed fracture of base of the coracoid process

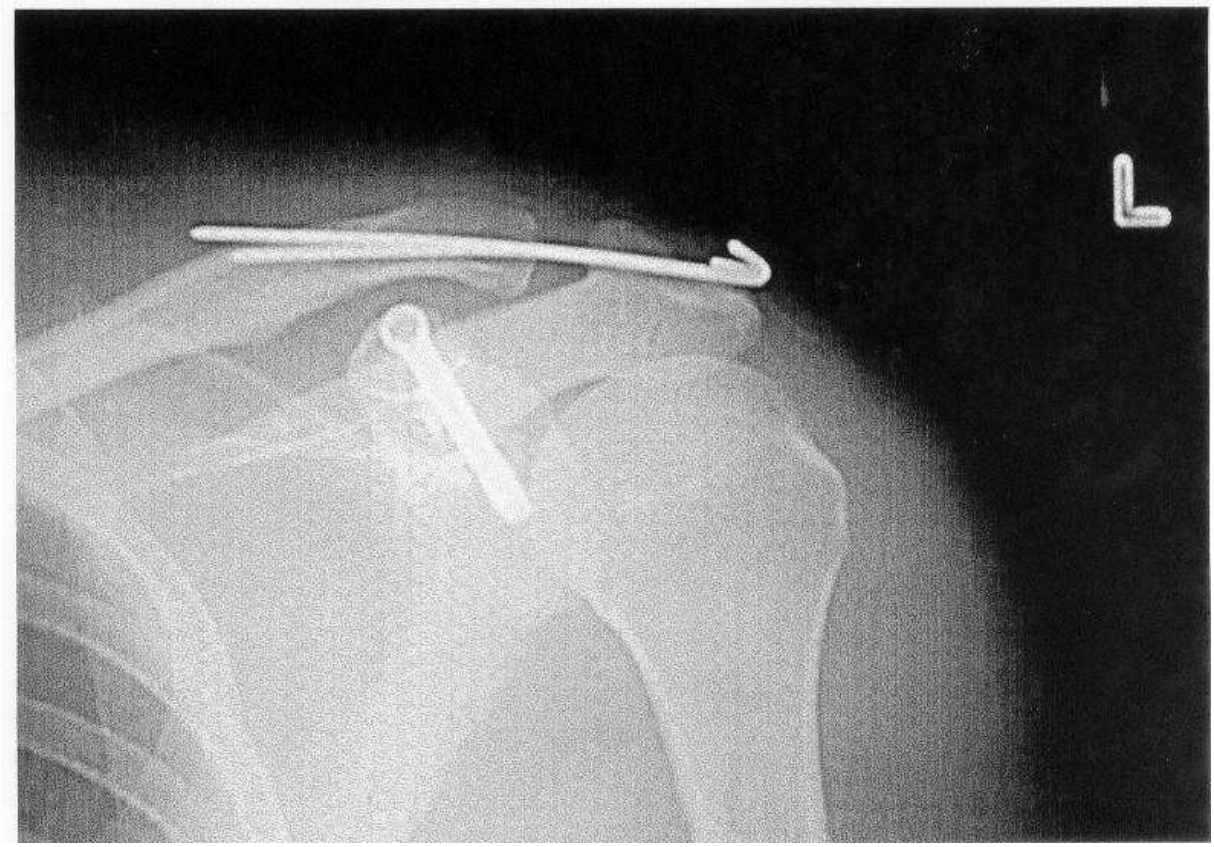

Figure 4: Anteroposterior radiograph performed after operation

Figure 5: Radiograph at 6 months after operation

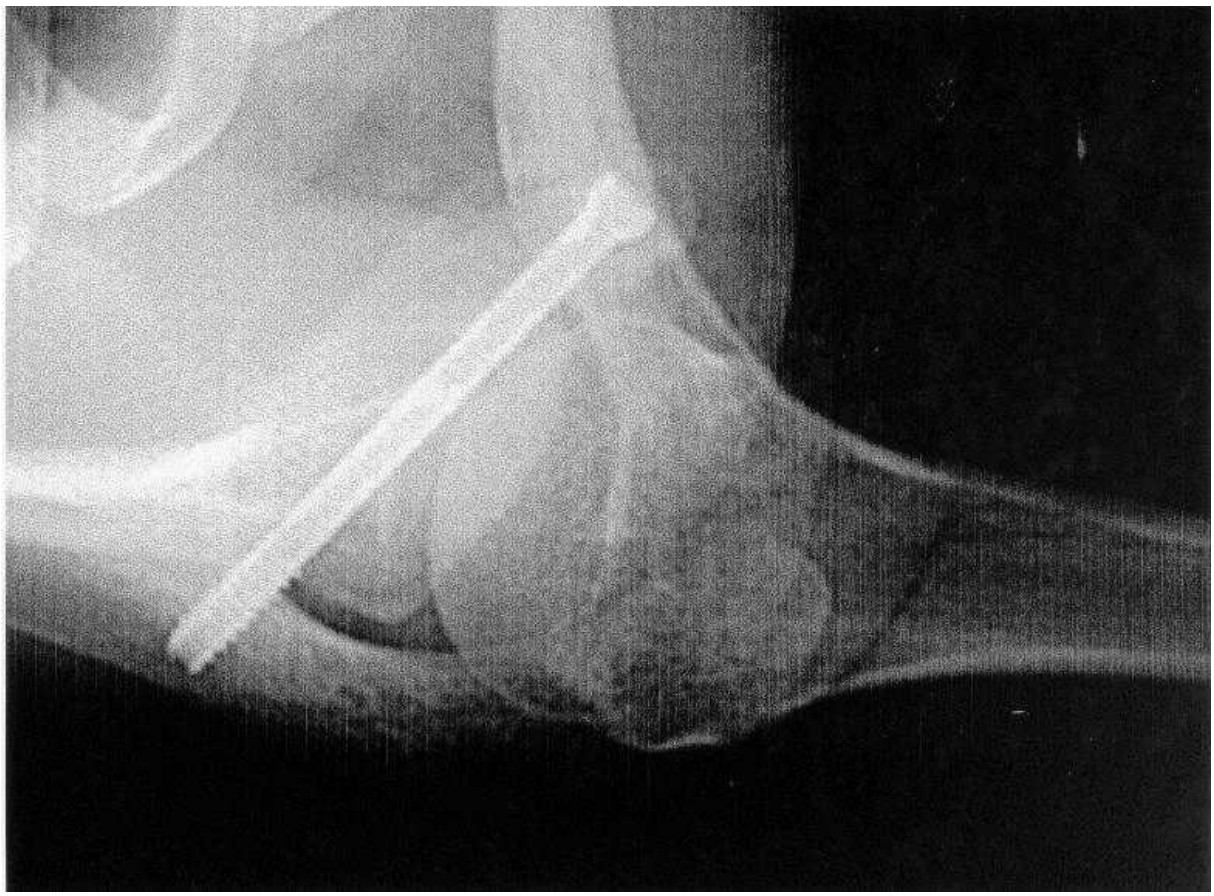

Figure 6: Stryker view at 6 months after operation confirmed union of the coracoid process fracture

References

1. Jacobs B, Wade PA (1966) Acromioclavicular joint injury. An end-result study. J Bone Joint Surg[Am] 48:475-86.

2. Lizaur A, Marco L, Cebrian R (1994) Acute dislocation of the acromioclavicular joint. Traumatic anatomy and the importance of deltoid and trapezius. J Bone Joint Surg [Br] 76:602-6.

3. Montgomery SP, Loyd RD (1977) Avulsion fracture of the coracoid epiphysis with acromioclavicular separation. Report of two cases in adolescents and review of the literature. J Bone Joint Surg [Am] 59:963-5.

4. Richards RR (1993) Acromioclavicular joint injuries. Instructional Course Lectures 42:254-69.

5. Rockwood CA Jr, Williams GR, Young DC (1998) Disorders of the acromioclavicular joint. In: Rockwood CA, Matsen FA (Eds) The shoulder, 2nd edition. WB Saunders Company, Philadelphia.

6. Wang KC, Hsu KY, Shih CH (1994) Coracoid process fracture combined with acromioclavicular dislocation and coracoclavicular ligament rupture. A case report and review of the literature. Clin Orthop 300:120-2.

7. Wilson KM, Colwill JC (1989) Combined acromioclavicular dislocation with coracoclavicular ligament disruption and coracoid process fracture. Am J Sports Med 17:697-8.

8. Zettas JP, Muchnic PD (1976) Fractures of the coracoid process base in acute acromioclavicular separation. Orthop Rev 5:77-9.